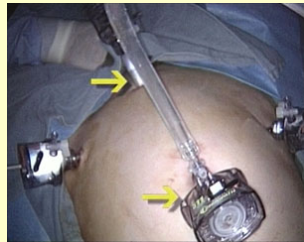


« View other Articles »

Title :: Total Laparoscopic Radical Hysterectomy and Bilateral Pelvic Lymphadenectomy using the Harmonic Scalpel

Division of Gynaecologic Oncology, Mount Sinai Medical Center, New York, NY



Authors

- ✉ **Farr Nezhat MD**
Professor of Gynecologic Oncology, Mount Sinai School of Medicine, New York, New York.

- ✉ **Nimesh Nagarsheth, MD**

- ✉ **Monica Prasad, MD**

Keywords

- adenocarcinoma
- harmonic scalpel
- lymphadenectomy
- laparoscopic total radical hysterectomy
- ureter


[Articles](#)

[Movie](#)

"The use of the harmonic scalpel in a laparoscopic radical hysterectomy for early cervical cancer has been described."

Article Information

Publication Date: 09/12/2005 **Update Date:** 11/12/2005

Clinical Case

The patient was a 30 year old female patient, para 0, who was diagnosed to have a cervical adenocarcinoma on a screening PAP smear.

A subsequent endocervical curettage revealed a moderately differentiated adenocarcinoma with focal invasion.

She underwent a cone biopsy and a repeated endocervical curettage which revealed an adenocarcinoma in situ with two foci of microinvasion consisting with a Stage IA2 lesion.

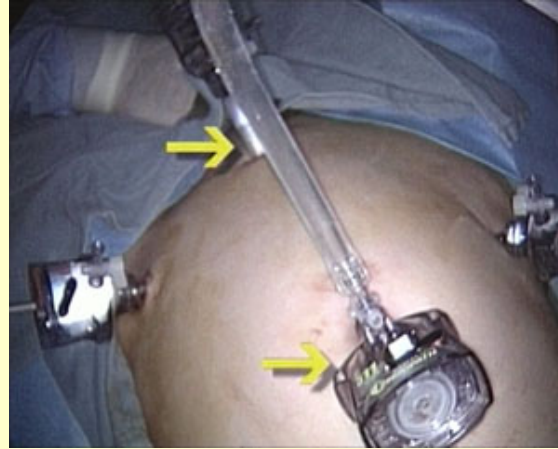
A preoperative CT scan of chest, abdomen and pelvis was negative for any visible disease.

The patient was offered a radical trachelectomy and a bilateral lymphadenectomy. Given that she did not want to maintain fertility, a radical procedure was chosen.

She was counselled about the risks and benefits of open versus laparoscopic radical hysterectomy and she agreed to proceed with the laparoscopic approach.

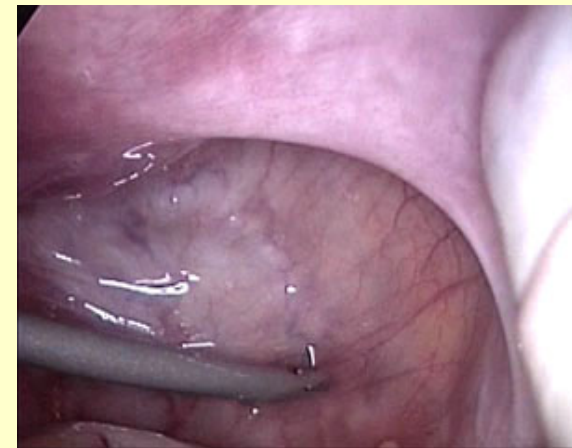Surgical technique

A ten millimetre trocar was placed through the umbilicus as well as through the suprapubic region. Two five millimetre trocars were placed in the bilateral lower quadrants. Prior to the procedure, cervical dilation was performed and a Humi uterine manipulator ([HUMI® - Harris-Kronner Uterine Manipulator Injector](#)) was placed into the uterus.



Video 1

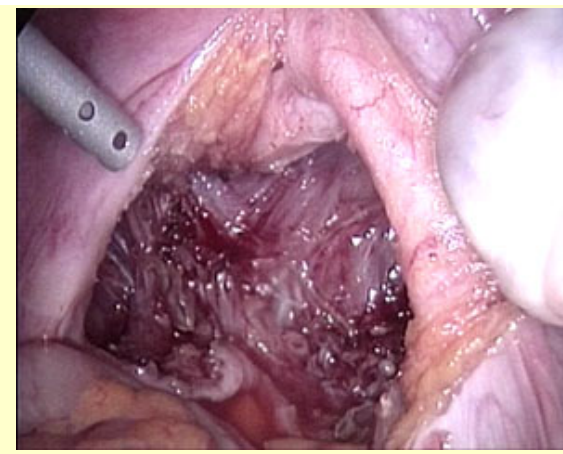
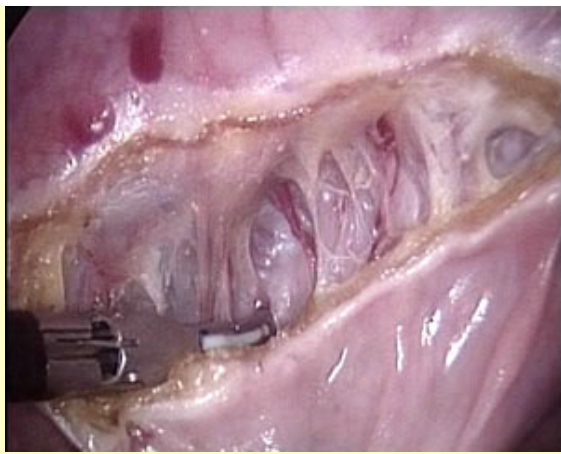Upon entry into the abdomen, exploration of the pelvic and abdominal cavity was performed and pelvic washings were obtained. The appendix was inspected.



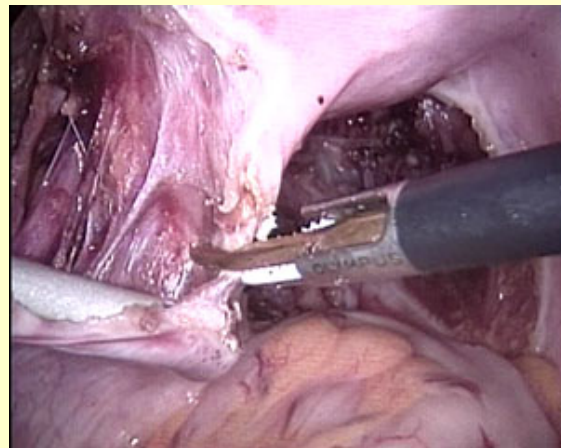
The procedure began with the development of the recto-vaginal septum. The harmonic scalpel was used to incise the peritoneum in the region between the uterosacral ligaments. The recto-vaginal space was developed. Careful dissection in the recto-vaginal space was facilitated by placing a sponge on a stick in the posterior vaginal fornix.



Video 2



Attention was then taken to the left pelvic sidewall. The left round ligament was grasped with the harmonic scalpel. The structure was coagulated and divided using this device by facilitating entry into the left pelvic sidewall.



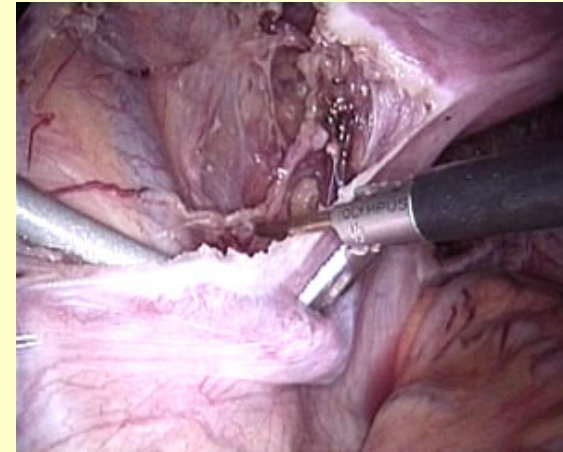
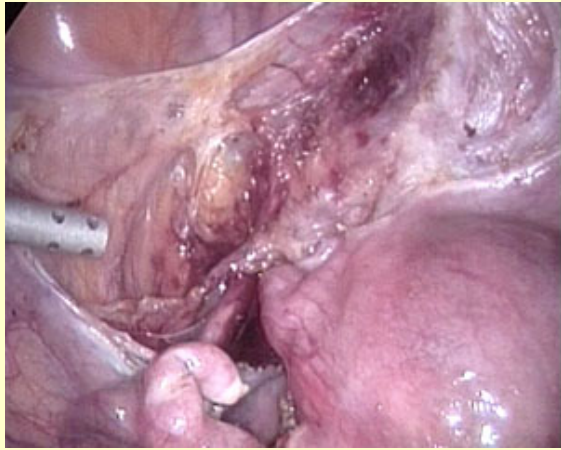Video 3

[Top](#)

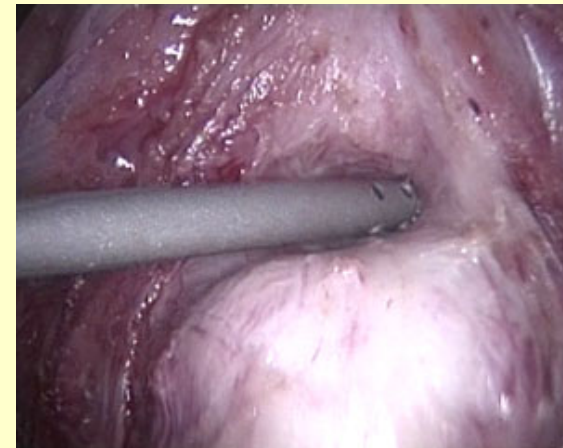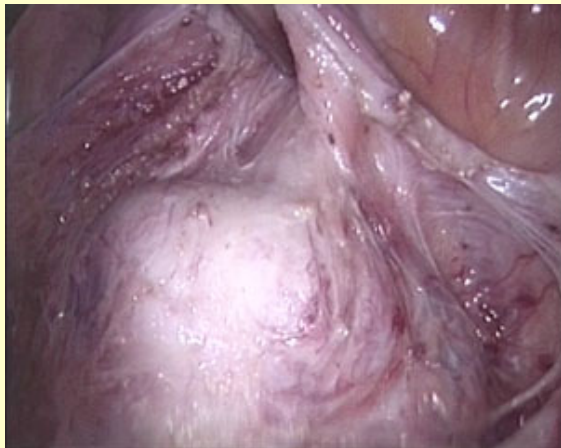The left uterovarian ligament and a portion of left fallopian tube was grasped, coagulated and divided using the harmonic scalpel.

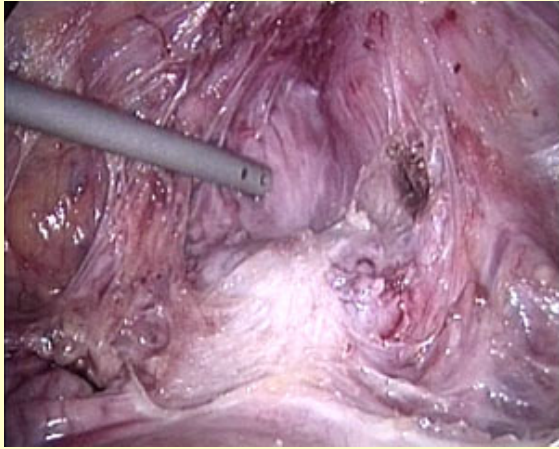
Dissection of anterior and posterior leaf of the broad ligament was then performed.

The harmonic scalpel could function as a grasper, dissector, coagulator and cutter minimizing the need for instruments exchange.



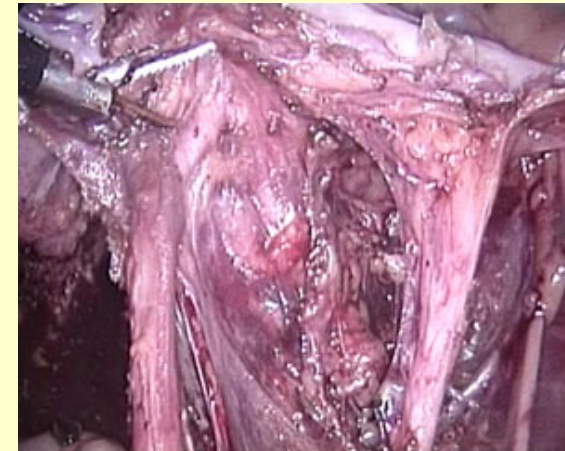
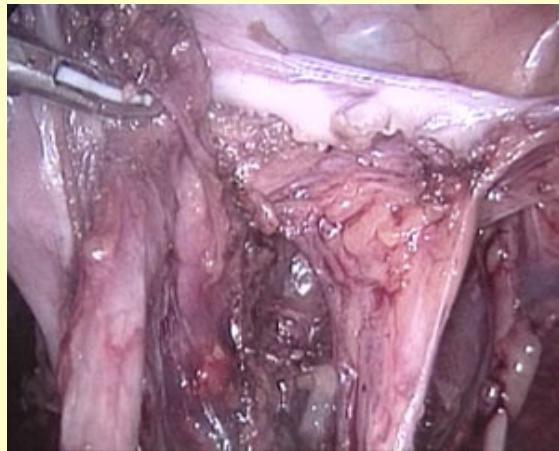Anteriorly the incision was carried down to the bladder flap. A sponge on a stick was placed into the anterior vaginal fornix, thus facilitating the creation of the vesico-vaginal space. Both blunt and sharp dissection was used to develop the vesico-vaginal space and isolation of the bladder pillars.





Video 4

The left ureter was dissected using both blunt and sharp dissection. The suction irrigator was used for blunt dissection and the harmonic scalpel was used to grasp the peritoneum and the incision was carried out in the medial leaf of the broad ligament.

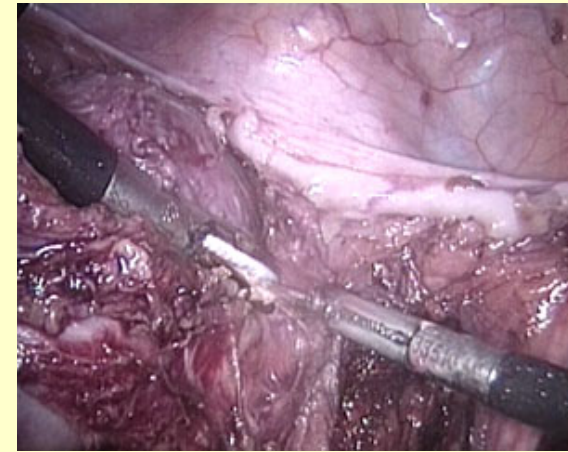
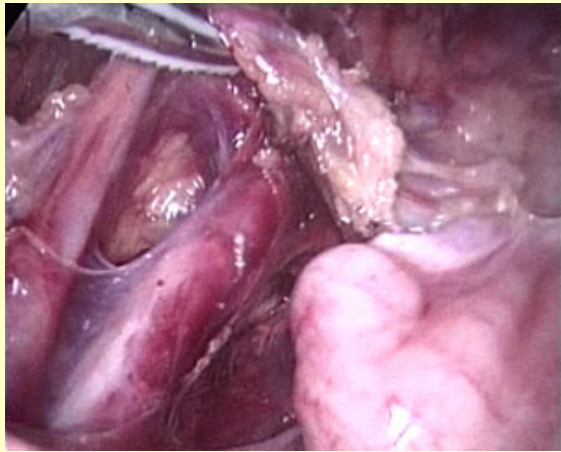


The harmonic scalpel was a safe instrument to use for this portion of the dissection as the use of ultrasonic energy minimizes the lateral thermal injury.

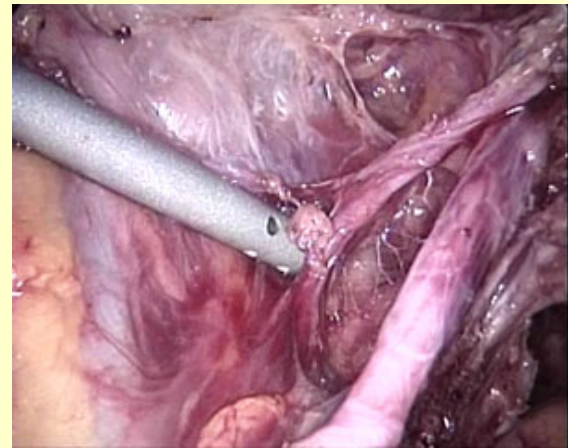
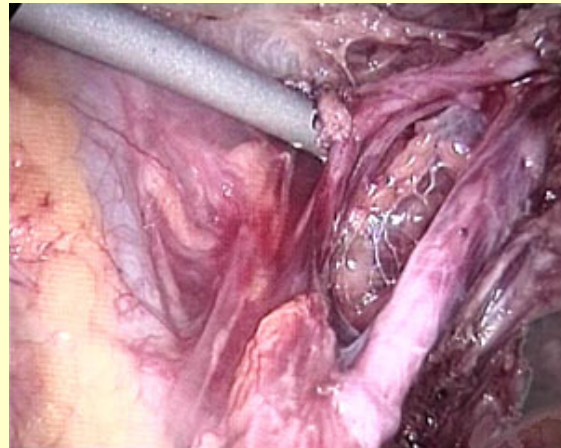


Video 5

The blunt dissection was used to completely isolate the left ureter from the surrounding structures. Afterward the left ureter could be seen entering in the tunnel.



The left obliterated hypogastric artery was placed on tension and the left uterine artery was then dissected from the origin and coagulated and divided using the harmonic scalpel.

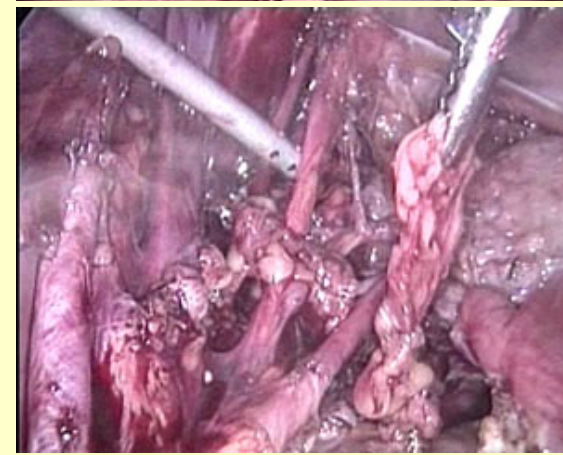
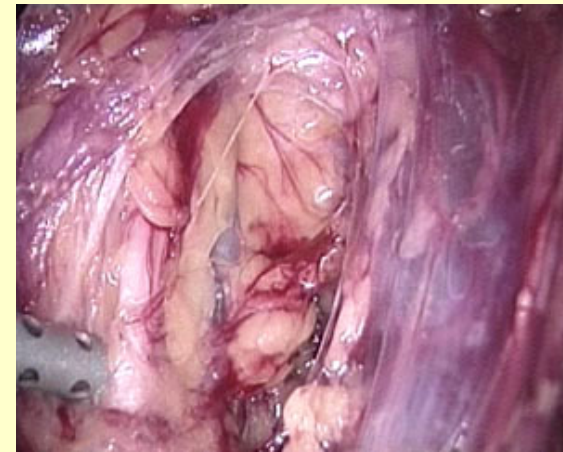
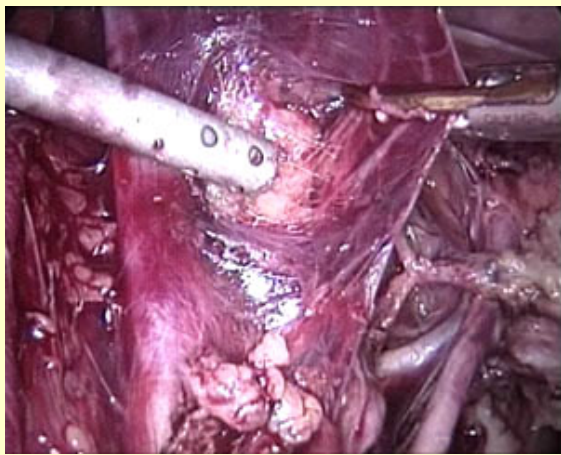
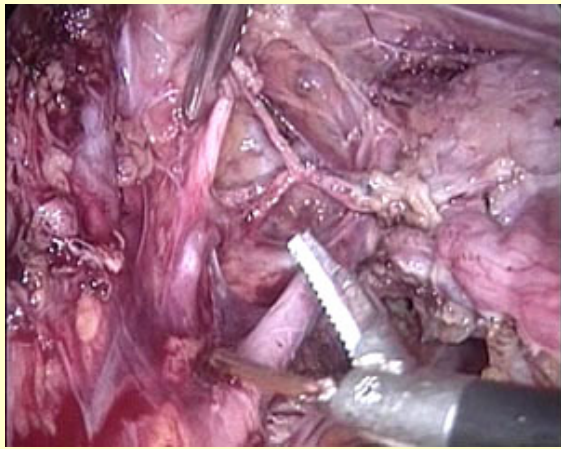


The left pelvic lymphadenectomy was performed in a standard fashion. Graspers were used to grasp lymphnode packets overlying the external iliac vessels. Blunt dissection with the suction irrigator was used to facilitate separation of lymphnode packets.

Coagulation with harmonic scalpel was also performed. The harmonic scalpel also functioned as a dissector during this portion of the procedure. The harmonic scalpel was used to create pedicles which could then be ligated and divided.

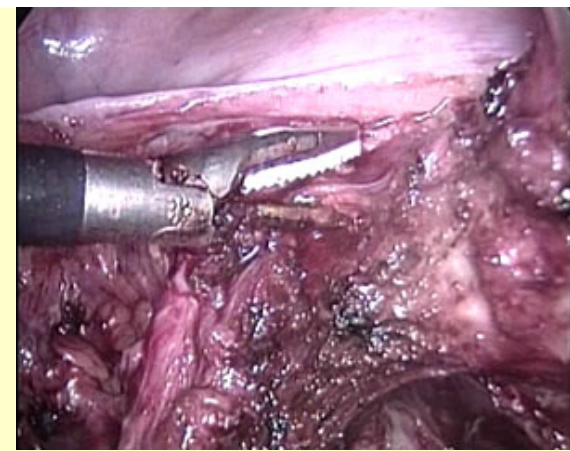
The perivesical space was developed. The obliterated umbilical artery was placed on tension and blunt dissection was used to open up this space. Entry into the left obturator space was accomplished using blunt dissection as well. The obturator space was entered with the suction irrigator. Careful removal of lymphatic tissue surrounding the left artery and nerve was performed. Lymphnode packets were removed through the suprapubic port.

[Top](#)

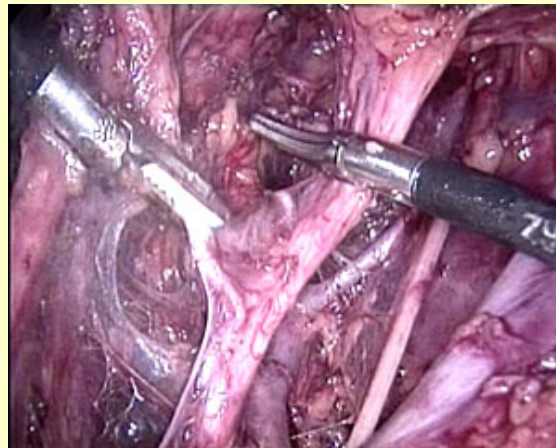


Video 6

Dissection of the left ureteral tunnel was accomplished using the harmonic scalpel. Medial attachments of the bladder pillar were grasped and coagulated with the harmonic scalpel and used to roll the ureter laterally.



Attention was then taken to the right side. The right uterine-ovarian ligament and the fallopian tube were grasped, coagulated and divided using the harmonic scalpel. Portion of broad ligament were also grasped, coagulated and divided. The right pelvic sidewall was opened in the standard fashion and the dissection was continued. Isolation of the right uterine artery was performed. The right uterine vein was seen just under the uterine artery. Blunt dissection was used to isolate this structures. The harmonic scalpel was used to grasp the right uterine artery. This structure was then coagulated. A sliding technique medial to lateral was performed with the harmonic scalpel to secure this vascular pedicle. Once divided, attention was taken to the right uterine vein. In a similar fashion, a sliding technique was used to coagulate this vascular bundle.



[Top](#)



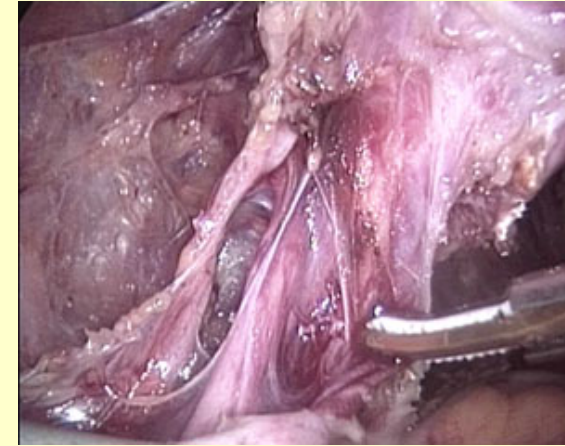
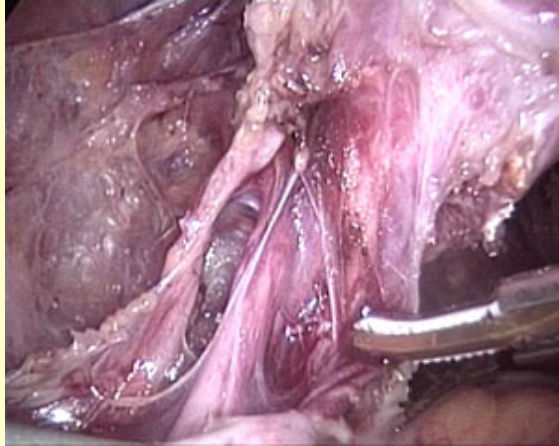
[Video 7](#)

The right ureter was isolated and dissected out of the right ureteral tunnel.

The harmonic scalpel was used to unroof the right ureter. Dissection with the harmonic scalpel facilitated this process.

Parametrial tissue was placed on medial tension facilitating unroofing of the ureter and dissection of all parametrial tissue. The right bladder pillar was also divided.

The uterosacral ligaments were grasped, coagulated and divided.

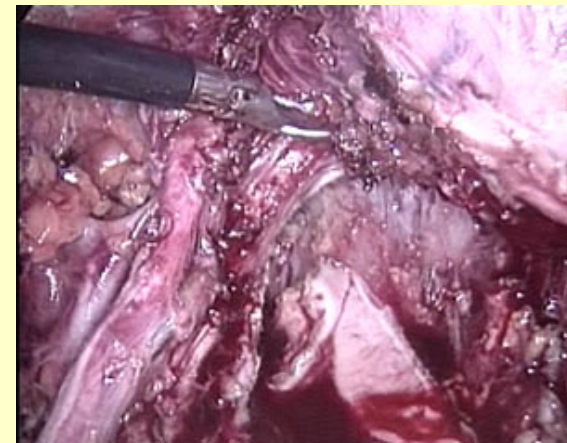


Video 8

The suction irrigator was used to help and facilitate minimizing of smoke plumes. The specimen was now free from all support tissues.

Removal of this specimen would be accomplished from a vaginal approach in a traditional fashion with the patient's legs rise.

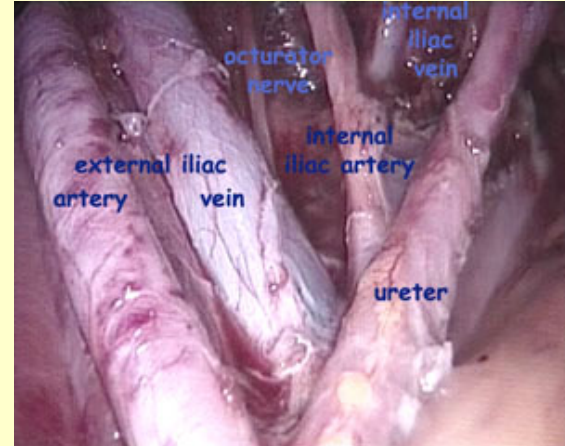
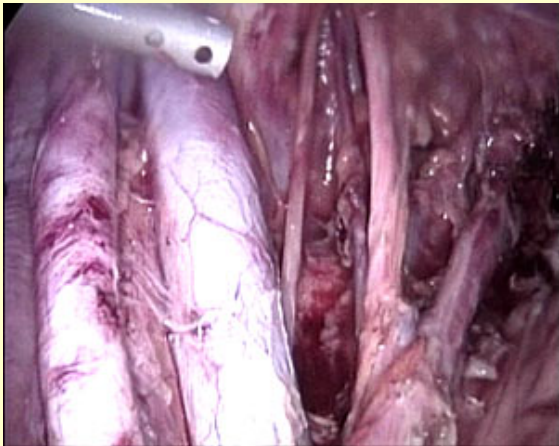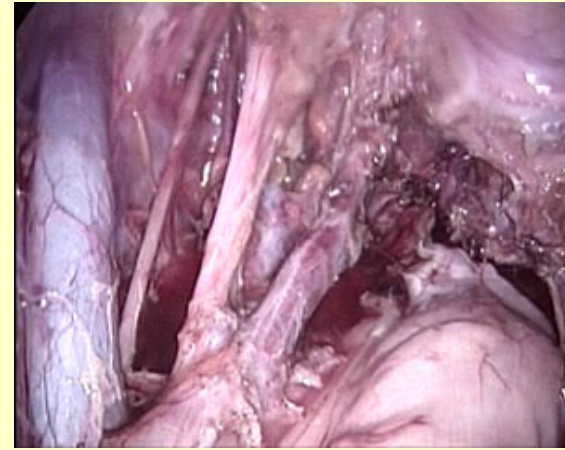
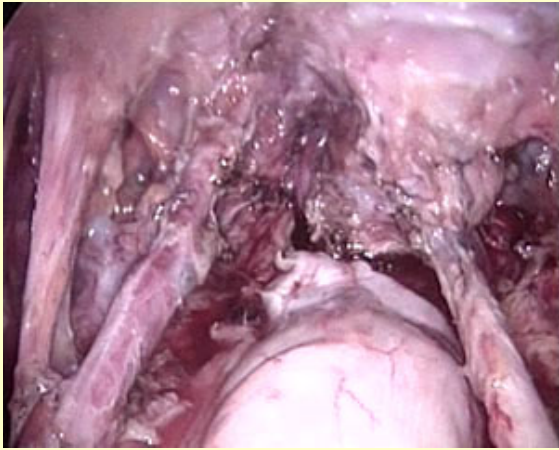
This approach was able to ensure adequate vaginal margins under a direct visualization. Entry into the vagina was facilitated with the harmonic scalpel cutting system. However the remaining portion of vaginal resection would be performed from the vaginal approach.



After the specimen was removed, the vaginal cuff was closed in a standard fashion transvaginally. Then the laparoscope was reintroduced and the pelvic anatomy was

reviewed. The left external iliac vessels, the left ureter, the epigastric vessels and the left artery and nerves were checked before ending the procedure.

Top



Video 9

Results

- Final Pathology
 - Washings negative
 - Uterus (112g) with a single 4 mm focus of residual adenocarcinoma in situ involving the cervix
 - Bilateral parametria and vaginal margins negative
 - 20 left pelvic lymph nodes and 14 right pelvic nodes negative

Results

- No intraoperative or postoperative complications
- Estimated blood loss = 100 cc
- Operative time = 4:45
- Discharged home on postoperative day 2
- Foley catheter was removed on postoperative day 5 in the office

[Top](#)

Conclusions

Conclusions

- Total laparoscopic radical hysterectomy and bilateral pelvic lymphadenectomy using the harmonic scalpel is feasible and safe
- Advantages include
 - Shorter hospital stay
 - Less morbidity
 - Overall quicker recovery period
 - Shorter interval to adjuvant therapy

Conclusions

- Advantages of the harmonic scalpel include
 - Less smoke generation than with traditional electrocautery
 - Functions as a grasper, dissector, coagulator, and cutter minimizing need for instrument exchange
 - Minimal lateral thermal tissue injury with coagulation occurring at lower temperatures than with electrosurgery or laser surgery
 - No transfer of electrical energy through the patient

[Top](#)

References

Cartron G, Leblanc E, Ferron G, et al. Complications of laparoscopic lymphadenectomy in gynaecologic oncology. A series of 1102 procedures in 915 patients. Gynecol Obstet Fertil. 2005;33:304-314. ([Medline](#))

Gil-Moreno A, Puig O, Perez-Benavente MA, et al. Total laparoscopic radical hysterectomy (type II-III) with pelvic lymphadenectomy in early invasive cervical cancer. J Minim Invasive Gynecol. 2005;12:113-120. ([Medline](#))

Malzoni M, Malzoni C, Perone C, et al. Total laparoscopic radical hysterectomy (type III) and pelvic lymphadenectomy. Eur J Gynaecol Oncol. 2004;25:525-527. ([Medline](#))

Nezhat F, Yadav J, Rahaman J, et al. Laparoscopic lymphadenectomy for gynecologic malignancies using ultrasonically activated shears: analysis of first 100 cases. Gynecol Oncol 2005;97:813-819. ([Medline](#))

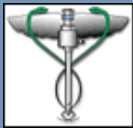
[top](#) 

Discussion Forum

[Click here to view or send comments pertaining to this article](#)

[top](#) 

[«View other Articles »](#)



The Trocar :: Online Videojournal of Gynecologic and Surgical Endoscopy

Powered by Gruppo Imatika srl
Design by Apolis Cantieri Multimediali

